

# Use of bivalirudin for heparin-induced thrombocytopenia after thrombolysis in massive pulmonary embolism: a case report

Sergio Fasullo · Sebastiano Scalzo · Giorgio Maringhini · Filippo Ganci · Alfonso Giubilato · Sergio Cannizzaro · Roberto Baglini · Debora Cangemi · Gabriella Terrazzino · Salvatore Paterna · Pietro Di Pasquale

Received: 9 December 2009 / Accepted: 22 April 2010 / Published online: 21 July 2010  
© Springer-Verlag London Ltd 2010

**Abstract** A 68-year-old man was referred to the emergency department 6 h after onset of sudden acute dyspnoea. Immediate ECG showed sinus tachycardia with the typical S1-Q3-T3 pattern and incomplete right bundle branch block. The echocardiogram showed the presence of mobile thrombus in the right atrium, a distended right ventricle with free wall hypokinesia and displacement of the interventricular septum towards the left ventricle. Lung spiral computed tomography (CT) showed bilateral pulmonary involvement and confirmed the picture of a thrombotic system in the right atrium and caval vein. Thrombolytic treatment with recombinant tissue plasminogen activator (rt-PA) and heparin (alteplase 10 mg bolus, then 90 mg over 2 h) was administered. Six hours after thrombolysis bleeding gums and significant reduction in

platelet count (around 50,000) were observed. Heparin was discontinued and bivalirudin (0.1 mg/kg bolus and 1.75 mg/kg per h infusion) plus warfarin was initiated and continued for 5 days until the international normalised ratio (INR) was within the therapeutic range (2.0–3.0) for 2 consecutive days, with concomitant platelet count normalisation. Lung spiral and lower abdominal CT before discharge did not show the presence of clots in the pulmonary arteries of the right and left lung. This case suggests that bivalirudin could offer promise for use in patients with heparin-induced thrombocytopenia (HIT) after thrombolysis for massive pulmonary embolism.

**Keywords** Bivalirudin · Heparin-induced thrombocytopenia · Pulmonary embolism · Thrombolysis

Disclaimer: The views expressed in this paper are those of the author(s) and not those of the editors, editorial board or publisher.

S. Fasullo · S. Scalzo · G. Maringhini · F. Ganci · A. Giubilato · S. Cannizzaro · G. Terrazzino · P. Di Pasquale (✉)  
Division of Cardiology “Paolo Borsellino”,  
G.F. Ingrassia Hospital,  
Via Val Platani 3,  
90144 Palermo, Italy  
e-mail: lehdi@tin.it

R. Baglini  
Mediterranean Institute Transplantation (ISMETT),  
Palermo, Italy

D. Cangemi  
Department of Cardiology, University of Palermo,  
Palermo, Italy

S. Paterna  
Department of Internal Medicine, University of Palermo,  
Palermo, Italy

## Introduction

Massive pulmonary embolism (MPE) is a potentially fatal event characterised by shock and/or hypotension (systolic blood pressure < 90 mmHg or a reduction of > 40 mmHg for 15 min that is not caused by new-onset arrhythmia, hypovolaemia or sepsis) [1]. The recently published European Society of Cardiology (ESC) guidelines on this topic suggest that absolute indications for thrombolysis are MPE with persistent hypotension or shock [2], and other recent clinical practice guidelines of the American College of Chest Physicians (ACCP) [3] confirm that thrombolytic therapy is the first-line intervention in people with high-risk pulmonary embolism and cardiogenic shock and/or arterial hypotension. Heparin treatment is initiated during thrombolysis and continued for at least 5–6 days in combination with oral anticoagulation until the international normalised

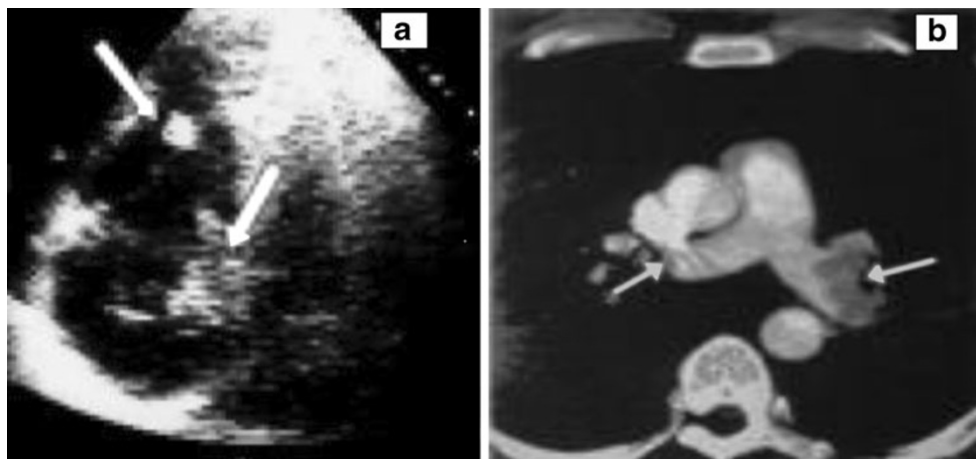
ratio (INR) is within the therapeutic range (2.0–3.0) for 2 consecutive days. Unfortunately, heparin-induced thrombocytopenia (HIT) can occur. We present here the case of a patient with MPE which was successfully thrombolysed and who developed an early type 2 HIT 6 h after heparin infusion, which probably could be attributed to the use of low molecular weight heparin (LMWH) in the previous months. To avoid coagulation rebound after heparin discontinuation, bivalirudin infusion in combination with oral anticoagulation (vitamin K antagonists) was initiated and continued until the INR was within the therapeutic range.

### Case report

A 68-year-old man (174 cm, 95 kg) was referred to the emergency department of our hospital 6 h after onset of sudden acute dyspnoea. There was a history of previous cardiovascular diseases, trauma and prostate cancer. Two months before, the patient had been subjected to surgical intervention for fracture of the right femur as a result of accidental trauma. The surgery went well, and the patient was treated with subcutaneous LMWH (enoxaparin) twice daily for 15 days. On admission the patient was dyspnoeic, cyanotic, haemodynamically unstable, hypotensive (80/50 mmHg) and tachycardic (136 bpm), with low oxygen saturation (82%) in oxygen with Venturi mask (6 l/min), respiratory rate 30 breaths/min, and with primary hypoxemia and metabolic acidosis (pH 7.30,  $pO_2$  54 mmHg,  $pCO_2$  23 mmHg,  $HCO_3$  16.2 mmol/l). Immediate ECG showed sinus tachycardia with the typical S1-Q3-T3 pattern and incomplete right bundle branch block (RBBB). Plasma samples were obtained to check laboratory parameters including troponin I, prothrombin time, activated partial thromboplastin time (APTT), INR, fibrin degradation products, D-dimers, and fibrinogen and N-terminal pro-brain natriuretic peptide (NT-pro-BNP) plasma levels which were measured every 6 h for the first 24 h then every 12 h

until clinical stabilisation and every 24 h subsequently. The echocardiogram performed immediately on admission showed the presence of mobile thrombus in the right atrium (Fig. 1) and also showed a normally contracting left ventricle, a distended right ventricle with free wall hypokinesia and displacement of the interventricular septum towards the left ventricle. In addition, an important tricuspid regurgitation and inferior caval vein dilatation were present. The spiral computed tomography (CT) showed bilateral pulmonary involvement more prevalent on the right and confirmed the picture of a thrombotic system in the right atrium and caval vein. In the absence of contraindications and after informing the patient thrombolysis was given (alteplase 10 mg bolus, then 90 mg over 2 h) followed by heparin according to APTT [3]. Arterial blood gas evaluation was also performed every 30 min after thrombolytic treatment, and then every 6 h up to stabilisation. We observed an improvement in oxygen saturation (>90%), an increase in blood pressure, a reduction in heart rate, complete absence of cyanosis and a reduction in dyspnoea 30 min after thrombolysis. The patient continued to receive heparin treatment (1,000 U/h and/or according to APTT) and oxygen delivered through a Venturi mask at a rate of 6 l/min. Echocardiography performed 6 and 12 h after thrombolysis showed a normal left ventricle with an ejection fraction of 65% and a less distended right ventricle and the disappearance of thrombi formation in the right atrium. Unfortunately, 6 h after thrombolysis a significant reduction in platelet count (around 50,000/ml) was observed (baseline 182,000/ml). In addition, 3 h after thrombolysis moderate bleeding gums (anterior and lateral) were also observed and these bleeding gums ceased completely 2 h after heparin discontinuation. The observed HIT raised the question of whether to continue the heparin or change the therapeutic strategy. We decided to discontinue heparin and to start infusion of bivalirudin in combination with oral anticoagulation (vitamin K antagonists). The bivalirudin was administered at a dose of 0.1 mg/kg bolus and 1.75 mg/kg per h infusion with dose

**Fig. 1** **a** Echocardiogram at entry: the *arrow* indicates the presence of mobile thrombus in the right atrium. **b** Spiral computed tomography: the *arrows* show bilateral pulmonary involvement is more prevalent on the right and confirmed the picture of a thrombotic system in the right atrium and caval vein



titration according to APTT and activated clotting time (ACT), controlled every 6 h for the subsequent days until the INR was within the therapeutic range (2.0–3.0) for 2 consecutive days. Platelets increased progressively in the subsequent days and a count of around 200,000/ml was observed 3 days after and the values were always in the normal range during hospitalisation and after discharge. In the subsequent days (2 days), Doppler echocardiography of the inferior limbs revealed deep thrombosis in the left femoral–popliteal veins. On days 4 and 5 an INR >2.0 was obtained and bivalirudin was discontinued (5 days), and only oral anticoagulation was maintained. Lung spiral CT, lower abdominal CT and Doppler echocardiography of the inferior limbs were repeated before discharge (9 days) and did not show the presence of clots in the pulmonary arteries of the right and left lung and also showed the disappearance of deep thrombosis in the left femoral–popliteal veins. The patient was discharged after 10 days of hospitalisation in good condition, with an INR of 2.5–3.5 with indication to continue warfarin therapy. After 3 months, a new lung spiral CT and Doppler echocardiography of the inferior limbs were performed and were negative for thrombotic formations. A ventilation perfusion scan was also negative. In the subsequent 6 months no episode of thrombosis recurred and the patient currently remains in good health and continues to receive warfarin therapy.

## Discussion

MPE can have potentially fatal consequences. Early thrombolytic therapy in conjunction with heparin may be life saving in MPE, especially if the patient is haemodynamically unstable [4, 5], and the current indication recommended for the use of thrombolytic therapy is MPE with hypotension [1–3, 6]. The risks and costs of thrombolysis also must be considered; bleeding is the most common complication of thrombolysis. In addition, because these patients also had to receive concomitant heparin, HIT as a severe adverse effect of heparin therapy can occur. The risk of this potentially fatal complication (mortality 8–20%) depends on both the type of heparin used and the clinical setting. The incidence is highest (3–5%) among patients who have undergone orthopaedic surgery and received unfractionated heparin. When HIT occurs the first step is to discontinue heparin. The next step is to treat HIT using an alternative type of anticoagulant. Even though the platelet count is low, it is important to avoid platelet transfusions, which can “add fuel to the fire” [3, 7]. Direct thrombin inhibitors (DTI) are a class of anticoagulant medications that do not cause HIT. Bivalirudin is the most recent DTI to be introduced to the market, but it is currently FDA approved with aspirin in patients with unstable angina

undergoing percutaneous transluminal coronary angioplasty. Although most cases occur in patients receiving unfractionated heparin, HIT can arise in venous thrombosis prophylaxis with an LMWH. We report a case of an early type 2 HIT in a postoperative orthopaedic patient complicated by deep venous thrombosis and MPE, which was successfully treated with thrombolysis but HIT developed in the early hours after fibrinolysis, which probably could be attributed to the long use of LMWH in the previous months (15 days). This is only a hypothesis because no sensitising test was performed. Also for this reason, we discontinued heparin infusion and to avoid coagulation rebound, and bivalirudin infusion in combination with warfarin was initiated and infusion maintained for 5 days without any side effects until an appropriate INR (2.0–3.0) was obtained. We recognise that, also in Italy, bivalirudin is not approved for HIT but the urgency of the case required a quick decision which was submitted to the Ethics Committee, which approved our choice. In conclusion, we report the efficacy of the combination of bivalirudin infusion (5 days) with warfarin when HIT occurs in the subsequent early hours post-thrombolysis in MPE. Bivalirudin could offer promise as an additional DTI for use in patients with HIT, but additional studies need to be performed to further define its use.

**Conflict of interest** None.

## References

1. Konstantinides S (2008) Clinical practice. Acute pulmonary embolism. *N Engl J Med* 359:2804–2813
2. Torbicki A, Perrier A, Konstantinides S et al (2008) Guidelines on the diagnosis and management of acute pulmonary embolism: the Task Force for the Diagnosis and Management of Acute Pulmonary Embolism of the European Society of Cardiology (ESC). *Eur Heart J* 29:2276–2315
3. Warkentin TE, Greinacher A, Koster A, Lincoff AM (2008) Treatment and prevention of heparin-induced thrombocytopenia: American College of Chest Physicians Evidence-Based Clinical Practice Guidelines (8th Edition). *Chest* 133(6 Suppl):340S–380S
4. Betrosian AP, Theodossiades G, Lambroulis G, Kostantonis D, Balla M, Papanikolaou M, Georgiades G (2003) Heparin-induced thrombocytopenia with pulmonary embolism and disseminated intravascular coagulation associated with low-molecular-weight heparin. *Am J Med Sci* 325(1):45–47
5. Dalla-Volta S, Palla A, Santolicandro A et al (1992) PAIMS 2: alteplase combined with heparin versus heparin in the treatment of acute pulmonary embolism. Plasminogen activator Italian multicenter study 2. *J Am Coll Cardiol* 20(3):520–526
6. Wan S, Quinlan DJ, Agnelli G, Eikelboom JW (2004) Thrombolysis compared with heparin for the initial treatment of pulmonary embolism: a meta-analysis of the randomized controlled trials. *Circulation* 110:744–749
7. Arepally GM, Ortel TL (2006) Clinical practice. Heparin-induced thrombocytopenia. *N Engl J Med* 355:809–817